

Case Report**The management of traumatic and non-traumatic dacryostenosis with endoscopic dacryocystorhinostomy****Dolly Irfandy*, Al Hafiz*, Rimelda Aquinas*, Hendriati****

*Department of Otolaryngology Head and Neck Surgery,

**Department of Ophthalmology,

Dr. M. Djamil Hospital / Faculty of Medicine Universitas Andalas, Padang

ABSTRACT

Background: Dacryostenosis is a condition of obstruction or stenosis of the nasolacrimal duct, causing excessive tearing. Endoscopic dacryocystorhinostomy (endo-DCR) is an endoscopic procedure for nasolacrimal duct obstruction management. **Purpose:** To report and analyze the result of endo-DCR in dacryostenosis cases that caused by traumatic and non-traumatic etiology. **Case report:** Two cases of nasolacrimal duct obstruction on 26 years old and 63 years old women. Endo-DCR was performed to the patients in join operation with the Ophthalmology Department. On 3 months follow up, there were no epiphora, nor recurrent infection. On anel test the nasolacrimal duct was patent. **Clinical question:** Is endo-DCR an appropriate procedure for traumatic and non-traumatic dacryostenosis cases? **Review method:** Literature search was performed with keywords: “dacryostenosis” AND “dacryocystorhinostomy” AND “endoscopy”. **Result:** The literature search through Cochrane Database, Science Direct, and Springer Link produced 104 published works, and after screening by entering keywords was carried out, resulting in 12 relevant literatures. Selection of the last 5 years produced 2 appropriate journals. **Conclusion:** Management of traumatic and non-traumatic dacryostenosis with endo-DCR provided excellent result. In these cases, the join operation between Otorhinolaryngologist and Ophthalmologist were very beneficial for the patients.

Keywords: dacryostenosis, nasolacrimal duct, endoscopy, dacryocystorhinostomy**ABSTRAK**

Latar belakang: Dakriostenosis adalah kondisi obstruksi atau stenosis duktus nasolakrimal sehingga keluar air mata yang berlebihan. Dakriosistorinostomi per endoskopi merupakan prosedur endoskopi untuk penatalaksanaan obstruksi duktus nasolakrimalis. **Tujuan:** Melaporkan dan menganalisis hasil dakriosistorinostomi per endoskopi pada kasus dakriostenosis yang disebabkan oleh trauma maupun non-trauma. **Laporan kasus:** Dilaporkan 2 kasus obstruksi duktus nasolakrimalis pada wanita usia 26 tahun dan 63 tahun. Pada pasien dilakukan dakriosistorinostomi per endoskopi, operasi bersama dengan Bagian Ilmu Kesehatan Mata. Setelah follow up 3 bulan, tidak ada epifora dan infeksi pada mata. Dengan pemeriksaan tes anel didapati duktus nasolakrimalis paten. **Pertanyaan klinis:** Apakah tindakan dakriosistorinostomi per endoskopi merupakan tindakan yang tepat untuk kasus obstruksi duktus nasolakrimalis karena trauma maupun non-trauma? **Telaah literatur:** Pencarian bukti dilakukan melalui Cochrane, Science Direct, dan Springer Link. **Hasil:** Didapatkan 104 literatur yang terkait. Setelah dilakukan skrining diperoleh 12 literatur yang relevan. Pemilihan jurnal 5 tahun terakhir dengan memasukkan kata kunci, diperoleh 2 jurnal yang sesuai. **Kesimpulan:** Penatalaksanaan dakriostenosis karena trauma ataupun non-trauma, dengan dakriosistorinostomi per endoskopi memberikan hasil yang memuaskan. Pada kedua kasus ini, kerja sama antara dokter spesialis THT-KL dan spesialis Mata memberikan manfaat untuk pasien.

Kata kunci: dakriostenosis, duktus nasolakrimalis, endoskopi, dakriosistorinostomi

Correspondence address: Dolly Irfandy, MD, ORL. Otorhinolaryngology Department Dr. M. Djamil Hospital / Faculty of Medicine Universitas Andalas. E-mail: dollyirfandy@med.unand.ac.id

INTRODUCTION

Dacryostenosis is a condition of obstruction or stenosis of the nasolacrimal duct, causing excessive tearing.¹ The obstruction could be an idiopathic inflammatory stenosis (primary acquired nasolacrimal duct obstruction) or secondary to trauma, infection, inflammation, neoplasm, or mechanical obstruction (secondary acquired lacrimal drainage obstruction). Obstruction of the nasolacrimal duct leading to stagnation of tears in pathologically closed lacrimal drainage system can result in dacryocystitis.² The most common cause of traumatic nasolacrimal duct obstruction is blunt injury encountered in traffic accident.³

Dacryocystorhinostomy (DCR) is the standard treatment for nasolacrimal duct obstruction. It is executed by removing the bone and mucosa between the lacrimal sac and the nose and creating a connection between medial wall of the sac and nasal mucosa.⁴ There are two techniques for the management of nasolacrimal duct obstruction management, i.e. external and endoscopic approach. External approach, which at the turn of the century was regarded as the gold standard treatment for nasolacrimal duct obstruction, requires a skin incision to access os lacrimal, followed by an external osteotomy, opening the nasal mucosa and creating the lacrimal sac flap from outside to inside. Some potential complications of this technique are cutaneous scar, injury to medial canthal, periorbital bruising and epistaxis.³

Endoscopic dacryocysto-rhinostomy (endo-DCR) in this last decade is more preferred for the treatment of primary nasolacrimal duct obstruction. A strong reason for this decision in general is patient's preference to avoid a facial scar as well as lesser complication rate compared to external DCR surgery.⁵

On endo-DCR procedure, the basic landmarks are the medial conchae and the lacrimal sac is anterior on the lateral wall, and it extends, in average, 8 mm above the middle concha junction (middle concha insertion on the lateral wall).⁴ The lacrimal puncta open at the medial ends of the upper and lower eyelids and drain into the lacrimal sac via the upper and lower canaliculus. The lacrimal sac is located in the lacrimal fossa and drains into the nasolacrimal duct, that runs within a bony canal created by the maxillary and lacrimal bones and opens into the inferior meatus of the nose.⁶

The purpose of this case presentation was to report the management and to evaluate the result of endo-DCR in traumatic and non-traumatic dacryostenosis cases.

CASE REPORT 1

A 26 years-old female was consulted from the Ophthalmology Department with complaint of excessive tearing intermittently on the right eye since 8 years prior to admission. She had a motorcycle accident 8 years ago, and her face hit the handlebar causing forehead and nose fractures. She underwent reconstructive surgery with fat graft augmentation on her forehead, and 3 times nose silicon augmentation in the Division of Plastic and Reconstructive Surgery of a private hospital. However, the silicon extruded, and her right eye was dry. Then she was suggested to frequently rub her right eye angle to excrete the tears.

After 4 years, as there was no improvement on her condition, she went to Dr. M. Djamil Hospital. She was diagnosed with dacryostenosis oculi dextra (OD) by an ophthalmologist and was suggested to undergo the procedure of endoscopic DCR in cooperation with the Ear-Nose-Throat

(ENT) Department. In ENT examination she was diagnosed with saddle nose, and deviated septum, and dacryostenosis OD (Figure 1), with *Peak Nasal Inspiratory flow* (PNIF) score 80.

Septorhinoplasty surgery with costal cartilage augmentation and fat grafting was implemented.

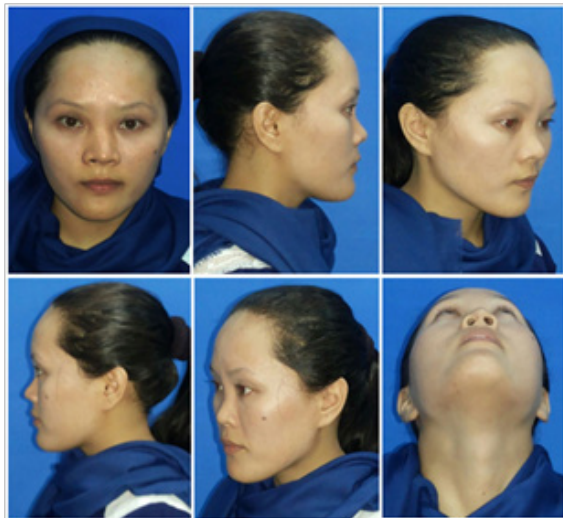

Figure 1. Before septorhinoplasty with costal cartilage augmentation and fat graft.

A year ago, she came to undergo the endo-DCR procedure. There was watery and swelling on the angle of the right eye (Figure 2a). There was no discharge, blurred vision, pain, nor redness on the right eye. There was no nasal obstruction, smelling disturbance, nor post nasal drip. There was no fullness sensation on both cheeks.

In ENT examination, the ear, nose, and throat were within normal limits. Nasoendoscopic examination showed normal result. Meanwhile, in ophthalmology examination the anel test was negative in right eye. Patient was diagnosed with dacryostenosis OD, and was suggested to do paranasal sinus CT imaging.

In 2 mm slices of axial and coronal paranasal sinus CT scan, an opacified right nasolacrimal duct was seen (Figure 2b).

Dacryocystography (DCG) showed contrast flow reached the distal end, and a partial stenosis on right nasolacrimal duct. Conclusion: partial stenosis of right nasolacrimal duct. Then, patient was suggested to undergo endo-DCR.

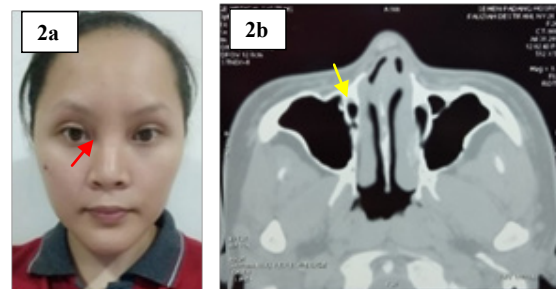


Figure 2a) Swelling on the angle of right eye (red arrow). **2b)** Paranasal sinus CT scan, opacified right nasolacrimal duct (yellow arrow).

In 2018, surgery was performed on patient, under general anesthesia. Nasal pledgets dripped with epinephrin: lidocain drops (2:1) were inserted into middle meatus and placed on the lateral nasal wall, and 1:200.000 epinephrin was injected to the lateral wall of nasal cavity anterior to middle turbinate and uncinate process. Incision was made above insertion of middle turbinate with no. 15 blade. A posterior mucosal flap was made to expose the lacrimal bone, and the mucosal flap was raised with a sickle knife. The bone was perforated with a diamond burr and Kerrison rongeur to expose the lacrimal sac, followed by marsupialization of the lacrimal sac. The nasal mucosal flap was then trimmed. A silastic tube was inserted into superior and inferior OD puncta, and excessive tears flew out. Fixation suture was placed into the lateral of nasal cavity. Anterior nasal packing was inserted into the nasal cavity.

Patient was hospitalized in ORL-HNS ward with diagnosis post endo-DCR with indication of dacryostenosis OD. She was given Ceftriaxone 2x1 gram (iv), Tranexamic acid 2x500 mg (iv), Ibuprofen 3x400 (oral).

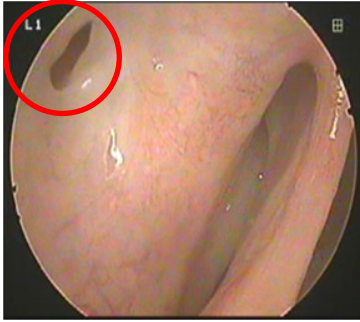


Figure 3. Endoscopic view of nasolacrimal duct 3 months post-surgery, ± 6 mm in diameter (red circle).

Two days post-operative, the anterior nasal packing was removed. Upon examination, the nasal cavity was wide, no bleeding, silastic tube was tied within nasal cavity. There was a decrease of excessive tears. Patient was discharged on the 3rd day. Medications were Levofloxacin 1x500 mg (oral) and Triamcinolone Acetonide nasal spray.

On 3 months follow up, there was no synechiae, no nasal congestion and nor excessive tears (Figure 3). Anel test showed patent lacrimal duct. Then the stent was removed by the Ophtalmology Department.

CASE REPORT 2

A 63 years-old woman (Figure 4) was referred by the Ophtalmology Department with symptom of excessive tearing intermittently on the left eye since 6 years previously. There was a history of reddish swelling on the angle of the right eye since 4 years. Two months prior to admission, the tearing on the left eye was continuous. There were no discharge and blurred vision. There were no nasal obstruction, decrease of smelling, and post nasal drip. There was no fullness sensation on the cheeks. There were no history of nasal fracture nor midfacial trauma. There was no history of consuming antiglaucoma medication, such as neostigmine or demacarium.

On ENT examination, ear, nose and throat were within normal limits. On Ophtalmology examination, anel test (-) in left eye. Patient was diagnosed with dacryostenosis oculi sinistra (OS).

On axial and coronal paranasal sinus CT scan, 2 mm slices without contrast, there was concha bullosa sinistra (Figure 5a & 5b). On dacryocystography, there was stenosis on left nasolacrimal duct (Figure 5c & 5d). Then, the patient was suggested to undergo endo-DCR.

In December 2019, endoscopic DCR surgery was performed under general anesthesia. Nasal pledgets dripped with epinephrin: lidocain drops (2:1) were inserted into middle meatus and placed on the lateral nasal wall, and 1:200.000 epinephrin was injected to the lateral wall of nasal cavity and to middle turbinate.

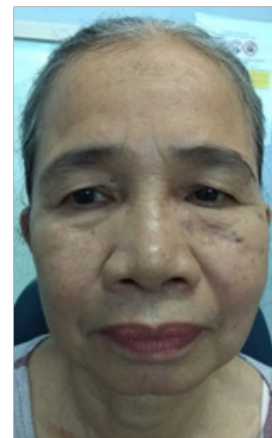


Figure 4. No swelling on the left eye.

Conchotomy was performed on the left middle turbinate, and an incision was made above the insertion of middle turbinate with a no. 15 blade. A posterior mucosal flap was made to expose the lacrimal bone, and the mucosal flap was raised with a sickle knife. The bone was perforated with a diamond burr and Kerrison rongeur to expose the lacrimal sac, followed by marsupialization of the lacrimal sac. The nasal mucosal flap was then trimmed. A silastic tube was inserted

into superior and inferior OD punctas, and excessive tears flew out. Fixation suture was placed into the lateral of nasal cavity. Anterior nasal packing was inserted into the nasal cavity.

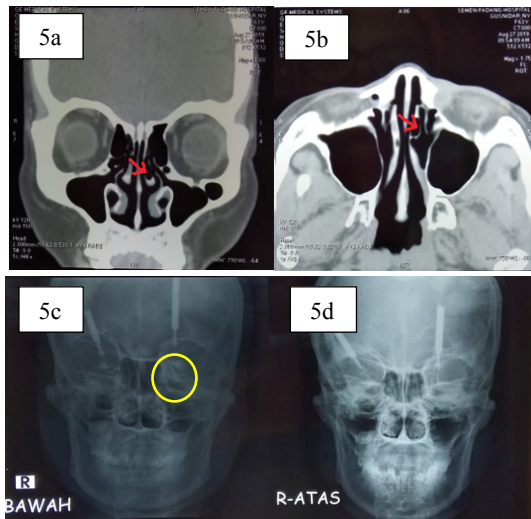


Figure 5a & 5b. Concha bullosa of left middle turbinate (red arrow). 5c & 5d. Dacryocystography with stenosis on left nasolacrimal duct (yellow arrow).

Patient was hospitalized in the ORL-HNS ward with diagnosis post endo-DCR with indication of dacryostenosis OS. She was given Ceftriaxone 2x1 gram (iv) and Natrium Diclofenac 3x50 mg (oral). On the 2nd day of follow-up, there was decrease of tears on the left eye. Upon evaluation, nasal cavity was wide, no bleeding, silastic tube was tied within nasal cavity. Patient was discharged on the 3rd day, and was given Cefixime 2x200 mg (oral), Natrium Diclofenac 3x50 mg (oral), and nasal washing with saline solution.

On 3 months follow-up, there was no synechiae, no nasal congestion and nor excessive tears. Patient had nasal irrigation of 0.9% NaCl 3x 20 ml in both nasal cavities.

CLINICAL QUESTION

Is endoscopic dacryocysto-rhinostomy procedure an appropriate procedure on traumatic and non-traumatic dacryostenosis?

REVIEW METHOD

Literature search through Cochrane database, Science Direct, Springer Link, appropriate for the clinical question. Screening was carried out filtered with eligibility criteria, i.e. 1) Type of study, projected with systemic review of prognostic, or cohort study with retrospective or prospective design, 2) Type of the outcome, concerning any recurrence or stable after optimal management.

RESULTS

After conducting literatures search on Cochrane Database, Science Direct, and Springer Link, based on the question: “is endoscopy dacryocystorhinostomy procedure an appropriate procedure on non-traumatic and traumatic dacryostenosis?”. It was found 104 articles related to the clinical question. Then, filtered with eligible criteria, resulting 12 relevant literatures. In the end, the authors obtained 2 studies to be appraised, i.e. Mukherjee³ and Roithman⁴.

Endoscopic dacryocystorhinostomy (endo-DCR) procedure provides excellent result, both for traumatic and non-traumatic dacryostenosis.

DISCUSSION

In case no.1, patient with trauma on frontal and nasal region causing dacryostenosis OD. The patient was diagnosed with saddle nose. According to Russel,⁷ fractures of the bony structure of the lacrimal fossa and nasolacrimal canal are associated with obstruction of nasolacrimal apparatus. Motor vehicle accident often causes severe blunt trauma on the midface and complex nasofrontal injuries. The osseous part of the nasolacrimal duct is most vulnerable, as fracture often propagate through the structurally weak bony lacrimal canal. Similarly, Schaefer¹ stated that nasal fracture is one of the causes of nasolacrimal duct obstruction.

In case no. 2, the cause of chronic nasolacrimal duct obstruction was unknown. In literatures, it is termed as primary acquired nasolacrimal duct obstruction. The majority of acquired obstruction occurs in adulthood, as a result of unexplained inflammation. The patients are more often female than male, starting with episodic epiphora (watery eyes), typically after the age of 40, and subsequently develop signs and symptoms of chronic or acute dacryocystitis.⁸ Bharathi et al.² found that the overall female to male ratio was 3.9:1. Chronic dacryocystitis in female subjects were significantly higher (80.9%) than in male (19.1%).

In case no.1, septorhinoplasty procedure was performed before endo-DCR. According to Almeida et al.⁹, correction of the nasal deformity is extremely important to re-establish the anatomy and respiratory physiology. Depression of the dorsum of the nose caused a saddle nose, generating lesion in the inner corner of the orbit. The lacrimal system may be affected, which lead to dacryostenosis. Bakshi¹⁰ stated that among 53 cases of rhinoplasty, 43 patients required septorhinoplasty surgical procedure with augmentation. The most common indication for septorhinoplasty measure was trauma, mainly after traffic accidents (58.5%).

In case no.1, patient came to ENT Department with extrusion of silicon graft from her nose. Autologous graft, particularly the cartilaginous type, has been the gold standard, especially because of its high acceptance rate, durability, virtual lack of immunogenic response, low infection, and extrusion rates.¹¹ Jung et al.¹² stated that the use of autologous rib cartilage has increasing popularity in recent years, due to the fact that it has abundant source of strong and resilient cartilage. They advocate the use of costal cartilage, especially for surgical correction of contracted nose, which typically requires abundant amount of strong cartilage to restore the structural framework of the nose and to

resist contracting forces of the skin and soft tissue envelope.

Moretti et al.¹¹ said that some surgeons preferred the central portion of the 5th to 8th rib. In our patient, the graft implanted was taken from the 8th costa. Before the patient came to ENT Department, she had been treated by plastic surgeon and underwent reconstructive surgery on her nose with silicon graft. According to Romo et al.¹³ silicon is used in the nose for soft tissue augmentation but it cannot provide structural support. If silicon implant is not secured in its place by the surrounding tissue, it may develop a chronic inflammation, and over time leads to seroma formation and causes implant extrusion.

Both patients came with main complaint of continuous tearing. According to Schaefer¹, tearing is the most common complaint. Other symptoms of nasolacrimal duct obstruction are swelling over the lacrimal sac, mucopurulent discharge, pain, dacryocystitis, and even cellulitis.⁴

According to Andalib et al.¹⁴, the term nasolacrimal duct stenosis describes patients with epiphora where nasolacrimal duct is partially patent to syringe (partial irrigation into the nose accompanied by some amount of reflux). Saha⁵ stated that nasolacrimal duct was the most common site of obstruction (82%) as compared to canalicular obstruction (24%). In case no.2, the obstruction site was the nasolacrimal duct.

Dacryocystography (DCG) is one of imaging methods that enables us to scrutinize the anatomy of lacrimal duct in patients with epiphora. It could precisely identify the site of stenosis of the excretory duct and provides reliable details for the indication and choice of the type of surgery to be performed. According to Lanciego et al.¹⁵ DCG is indicated for complete obstruction and partial obstruction of lacrimal duct. Francisco et al.¹⁶ stated that epiphora is the most common indication for DCG examination procedure.

On our patient's paranasal CT scan, an opacification in the right nasolacrimal duct was seen. According to Mukherjee et al.³, although DCG is the gold standard for examination of lacrimal system, DCG could not describe the structure of the soft tissue and bone around the sacculus or nasolacrimal duct. Paranasal CT scan is more useful for evaluating post-traumatic epiphora. According to Choi et al.¹⁷, CT-scan could outline nasolacrimal sac anatomy and its relation with the drainage system. CT imaging is useful in evaluation of periocular pathology with detailed imaging in a short scan time. Russel et al.⁷ opined that axial CT is well suited for inspecting fracture of lacrimal bony structure.

Before the endo-DCR procedure was discovered in 1989 by McDonough and Meiring, DCR was executed through an external approach, but this approach leaves a cutaneous scar and the potential for injury to the medial canthal structures, cerebrospinal fluid rhinorrhea and functional interference with physiological action of lacrimal pump.^{18,19} Yigit et al.¹⁸ reported full success was achieved in 69.9% of patients with external DCR group, whereas in endo-DCR full success rate was 89.7%. Full success was achieved when epiphora under normal conditions resolved, no recurrent infection, and minimal or no reflux was seen upon lacrimal irrigation.

In this case, diamond burr and rongeur forceps were used to create the rhinostomy. According to Jutley et al.²⁰ mechanical approach using diamond burr brings greater successes than using laser. Sobel et al.²¹ concluded that combination of rongeur forceps and diamond burr in endo-DCR is superior than external DCR, and also endo-DCR technique using rongeur is superior than external DCR.

According to Penttila et al.²² endo-DCR is indicated in the management of epiphora and infection related to primary acquired nasolacrimal duct obstruction and secondary

acquired nasolacrimal duct obstruction when the obstruction site is located in the nasolacrimal sac or nasolacrimal duct. In our patient, there was stenosis in nasolacrimal duct, so endo-DCR was an appropriate procedure. Yigit et al.¹⁸ stated that percentage of success of endo-DCR was 89.7% compared to external DCR 69.9%. Factors affecting the success of endo-DCR are the localization of the sac and obtaining enough opening. The main disadvantages of endoscopic DCR are mainly the difficulty to perform surgery in small surgical field and difficulty in removing sufficient amount of bone to expose the sac. But these problems could be overcome by experience and more adequate instruments. Furthermore, silicon stent could establish continuous flow to secure open ostium.

According to Khan et al.¹⁹ endo-DCR procedure allows direct visualization of lacrimal sac pathology. Assessment of failure could also be viewed endoscopically, so mistakes could be corrected immediately. Saha et al.⁵ stated that the use of nasal endoscope makes shorter surgery time than external DCR, also lack of external incision, easier to perform postoperative assessment of the ostium patency, and quicker return to work and lesser follow-up appointments, which are pleasant for the patient.

In other research, Peng et al.²³ mentioned that endoscopic approach was superior over conventional approach in numerous aspects, such as avoidance of skin trauma, scar tissue formation, improved hemostasis, decreased incidence of intraoperative bleeding, and better visualization of the anatomical structure. In the case of female patient, Bharangar et al.²⁴ stated that scar caused by external DCR could be prevented by performing endo-DCR procedure. On his research, among 578 patients, there were about 4-5% failure after 7 days follow-up, who came with epiphora. It was easily corrected under direct vision of endoscope by removing crust, granulation tissue, suction clearance over the endonasal

ostia of sac under no sedation, in outpatient clinic.

Both our patients were given post-operative medication i.e. antibiotic, analgetic, and topical corticosteroid. According to Roithmann et al.⁴ patient should be given oral antibiotic for 5-7 days, along with ophthalmological drops with antibiotics and steroid for 14 days. Mukherjee et al.³ suggested to give patients antibiotic-steroid eyedrops for 4 weeks, and oral antibiotic for 5 days. Yakopsan et al.²⁵ stated that nasal steroid spray should be prescribed to decrease nasal congestion and help prevent post-operative scarring.

Roithmann et al.⁴ reported some complications of endo-DCR, including failure in locating the lacrimal sac, insufficient osteotomy, granulation tissue, fibrosis or local synechia, bone neogenesis, and insufficient opening of the lacrimal sac. They found that the complication rate of endo-DCR in experienced hands are never higher than 2%. According to Alherabi et al.²⁶, several factors are responsible for the failure of endoscopic DCR, including the location of the bony ostium and its size, as well as adequate exposure and opening of the lacrimal sac. To achieve the best result, recent studies suggest the importance of opening the lacrimal sac ostium as wide as possible.

On case number 1, upon 3 months post-operative follow-up, there were no nasal congestion nor epiphora. Anel test result was patent duct. Silicon stent was removed after 3 months by ophthalmologist. This was in accordance with Farahani et al.²⁷ and Viswanatha et al.²⁸ who advised to remove the silicon stent of endo-DCR after 3 months. Patency of lacrimal system was assessed by rigid endoscopy and irrigation with saline. The resolution was accepted as a successful result. According to Sobel et al.²¹ the success of endo-DCR was defined as improvement in tearing and patency on irrigation after at least 4 months of follow-up.

In conclusion, the management of traumatic and non-traumatic dacryostenosis with endo-DCR provides excellent result and good access to intranasal. Under endoscopic guidance nasal anatomy is understood directly, managed accordingly, the nasolacrimal sac was approached directly under vision and so at the time of surgery the results could immediately be known. Also, application of silicon stent was essential to establish osteal opening.

REFERENCE

1. Schaefer, DP. Acquired etiologies of lacrimal system obstructions. In: Cohen AJ, Mercendetti M, Brazzo BG, editors. The lacrimal system diagnosis, management and surgery. New York: Springer, 2006. pp.43-6.
2. Bharathi JM, Ramakrishnan, Maneksha V, Velusamy. Comparative bacteriology of acute and chronic dacryocystitis. *Eye*. 2007; 1-8.
3. Mukherjee B, Dhobekar M. Traumatic nasolacrimal duct obstruction: Clinical profile, management, and outcome. *Eur J Ophthalmol*. 2013;23(5):615-22.
4. Roithmann R, Burman T, Wormald PJ. Endoscopic dacryocystorhinostomy. *Braz J Otorhinolaryngol*. 2012;78(6):113-21.
5. Saha R, Sinha A, Phukan JP. Endoscopic versus external approach dacryocystorhinostomy : A comparative analysis. *Indian Journal of Clinical and Experimental Ophthalmology*. 2015;1(3):134-42.
6. Wasl H, Lubbe D. Endoscopic dacryocystorhinostomy (DCR) surgical technique. (Figure 1):1-11.
7. Russell EJ, Czervionke L, Huckman M, Daniels D, McLachlan D, Al RET. CT of the inferomedial orbit and the lacrimal drainage. *AJNR*. 1985;(October):759-66.
8. Linberg J V, McCormick SA. Nasolacrimal duct obstruction a clinicopathologic report and biopsy technique. *Ophthalmology*. 93(8):1055-63.
9. Almeida FS De, Miñarro LL, Píalarissi PR. Surgical correction of the saddle nose : Case Report. *Intl. Arch Otorhinolaryngol*. 2009;13(4):450-54.

10. Bakshi J, Patro SK. Septorhinoplasty: Our experience. *Indian J Otolaryngol Head Neck Surg.* 2017;69(3):385-91.
11. Moretti A, Sciuto S, Sciuto B. Rib grafts in septorhinoplasty. *Acta Otorhinolaryngologica Italica.* 2013;33:190-95.
12. Jung D, Tan K, Jin S. Nasal tip surgery : Nasal lengthening and augmentation in Asian rhinoplasty. *Journal of Cosmetic Medicine.* 2017;1(1):8-15.
13. Romo T, Pearson JM. Nasal Implants. *Facial Plast Surg Clin North Am.* 2008;16(1):123-32.
14. Andalib D, Nabie R, Kazemi E. The effect of stenosis nature on success of silicone intubation for nasolacrimal duct stenosis in adults. *Iran J Ophthalmol.* 2014;26(3):166-69
15. Lanciego C, De Miguel S, Perea M, et al. Nasolacrimal stents in the management of epiphora: Medium-term results of a multicenter prospective study. *J Vasc Interv Radiol.* 2001;12(6):701-10.
16. Francisco FC, Carvalho ACP, Francisco VFM, Francisco MC, Neto GT. Evaluation of 1000 lacrimal ducts by dacryocystography. *Br J Ophthalmol.* 2007;91(1):43-6.
17. Choi SC, Lee S, Choi HS, Jang JW, Kim SJ, Lee JH. Preoperative computed tomography findings for patients with nasolacrimal duct obstruction or stenosis. *Korean J Ophthalmol.* 2016;30(4):243.
18. Yigit O, Samancioglu M, Taskin U, Ceylan S, Eltutar K, Yener M. External and endoscopic dacryocystorhinostomy in chronic dacryocystitis : comparison of results. *Eur Arch Otorhinolaryngol.* 2007;264:879-85.
19. Khan MKH, Ma H, Hossain MJ, Rahman. Comparative study of external and endoscopic endonasal dacryocystorhinostomy for the treatment of chronic dacryocystitis. *JAFMC Bangladesh.* 2011;7(2):15-7.
20. Jutley G, Karim R, Joharatnam N, Latif S, Lynch T. Patient satisfaction following endoscopic endonasal dacryocystorhinostomy : Patient satisfaction following endoscopic endonasal dacryocystorhinostomy : a quality of life study. *Eye.* 2013;27(9):1084-89.
21. Sobel RK, Aakalu VK, Wladis EJ, Bilyk JR, Yen MT, Mawn LA. Ophthalmic technology assessment: A comparison of endonasal dacryocystorhinostomy and external dacryocystorhinostomy. *A Report by the American Academy of Ophthalmology. Ophthalmology.* 2019;126(11):1580-85.
22. Penttilä E, Smirnov G, Tuomilehto H, Kaarniranta K, Seppä J. Endoscopic dacryocystorhinostomy as treatment for lower lacrimal pathway obstructions in adults: Review article. *Allergy Rhinol.* 2015;6(1):12-19.
23. Peng W, Tan B, Wang Y, Wang H, Wang Z. Nasal and lacrimal flap technique in endoscopic dacryocystorhinostomy. *Sci Rep.* 2017;(July):1-6.
24. Bharangar S, Singh N. Endoscopic endonasal dacryocystorhinostomy : Best surgical management for DCR. *Indian J Otolaryngol Head Neck Surg.* 2012;64(4):366-69.
25. Yakopson VS, Flanagan JC, Ahn D, Luo BP. Dacryocystorhinostomy: History, evolution and future directions. *Saudi J Ophthalmol.* 2011;25(1):37-49.
26. Alherabi A, Marglani O, Herzallah I, Shaibah. Endoscopic anatomy of the lacrimal sac for dacryocystorhinostomy: A cadaveric study. *Saudi Med J.* 2017;38(3):245-50.
27. Farahani F, Bazzazi N, Hashemian F. Failed dacryocystorhinostomy due to retained silicone tube : A Case Report. *The Iranian Society of Ophthalmology.* 2010;22(4):2-5.
28. Viswanatha B, Vijayashree MS. Silicone stenting and polypropylene stenting in endoscopic dacryocystorhinostomy : A prospective comparative study. *Research in Otolaryngology.* 2015;4(4): 49-53.