

**Case Report****Hearing loss in a child with hydrocephalus****Muyassaroh\*, Ahmad Effendi\*\*, Dwi Marliyawati\*\***

\*Otolaryngology Head and Neck Surgery Dr. Kariadi Hospital, Semarang

\*\*Otolaryngology Head and Neck Surgery, Faculty of Medicine Universitas Diponegoro, Semarang

**ABSTRACT**

**Background:** Hydrocephalus in children is a complex condition that can affect neurodevelopmental disorders, including hearing impairment. Changes in pressure and amount of cerebrospinal fluid (CSF) could cause endolymph hydrops which results in inner ear dysfunction. **Objective:** To study the mechanism of how hydrocephalus could cause hearing loss. **Case:** A 1 year 7 months old girl with hydrocephalus and global development delay, and hearing loss. The patient underwent hearing tests with Otoacoustic Emission (OAE), tympanometry, and Evoked-Auditory Brain Response (ABR). The patient underwent ventriculoperitoneal (VP) shunt surgery and hearing rehabilitation. Three months post-surgery patient could respond to sound stimulation. **Clinical question:** How is the mechanism of hydrocephalus in inducing hearing loss? **Method:** Literature search was performed through PubMed and Google Scholar, with “hearing loss” AND “hydrocephalus” AND “children” as the keywords. The search obtained 101 journals. **Result:** Publications that fulfilled the inclusion criteria were 4 journals. Hearing loss was caused by fourth ventricular pressure. Hydrocephalus could also cause hearing loss through the mechanism of the relationship among perilymph, endolymph, and CSF pressure. VP shunt or ventriculotomy was supposed to be able to improve the inner ear function. **Conclusion:** Hydrocephalus causes endolymphatic hydrops which results in hearing loss.

**Keywords:** hearing loss, hydrocephalus, endolymphatic hydrops, inner ear dysfunction

**ABSTRAK**

**Latar belakang:** Hidrosefalus pada anak merupakan kondisi yang kompleks dan dapat mempengaruhi perkembangan saraf, termasuk terjadinya gangguan pendengaran. Jumlah cairan serebrospinal yang berlebihan dapat menyebabkan hidrops endolimf yang berakibat disfungsi telinga dalam. **Tujuan:** Mempelajari bagaimana kasus hidrosefalus menyebabkan kurang dengar. **Laporan kasus:** Seorang anak perempuan usia 1 tahun 7 bulan, dengan hidrosefalus disertai gangguan perkembangan dan kurang dengar. **Pertanyaan klinis:** Bagaimana hidrosefalus dapat menyebabkan gangguan pendengaran? **Metode:** Pencarian literatur melalui PubMed dan Google Scholar dengan kata kunci “hearing loss” DAN “hydrocephalus” DAN “children” secara sistematis sesuai dengan kriteria inklusi. **Hasil:** Didapatkan 4 jurnal laporan kasus yang dapat dianalisis. Hidrosefalus dapat menyebabkan gangguan pendengaran melalui mekanisme hubungan antara perilimf, endolimf dan tekanan likuor serebrospinalis (LSS). Perubahan tekanan dan volume LSS menyebabkan hidrops endolimf yang berakibat pada disfungsi telinga dalam. Perbaikan tekanan LSS dengan pemasangan ventriculoperitoneal (VP) shunt atau ventrikulotomi dianggap dapat memperbaiki fungsi telinga dalam. **Kesimpulan:** Hidrosefalus menyebabkan hidrops endolimf yang berakibat terjadinya gangguan pendengaran.

**Kata kunci:** kurang dengar, hidrosefalus, hidrops endolimf, disfungsi telinga dalam

**Correspondence address:** Muyassaroh. Department of Otolaryngology, Head and Neck Surgery, Dr Kariadi Hospital, Jl. Dr. Soetomo 16, Semarang. Email: muyastht@gmail.com

## INTRODUCTION

Hydrocephalus is a clinical condition with cranial enlargement in infants and children due to increased cerebrospinal fluid (CSF) volume caused by multifactorial, including vascular disease, impaired CSF absorption and congenital causes.<sup>1-3</sup>

Congenital hydrocephalus is rare, estimated at 0.3-0.6 per million live births. Most cases were infants (46.25%), and 5% neonates. Male are more likely to develop hydrocephalus. Hearing loss appears to be a common occurrence in hydrocephalus even if it is rare.<sup>4,6</sup>

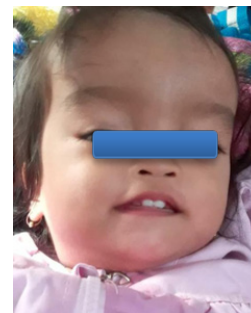Hydrocephalus causes hearing loss through the connection mechanism between CSF pressure, perilymph, and endolymph. The perilymph communicates with the CSF via the cochlear aqueduct, while the endolymph communicates with the endolymphatic vessels.<sup>1,4</sup> Pressure disturbances and CSF loss that leading to inner ear dysfunction are still controversial. Ventriculoperitoneal (VP) shunt or ventriculotomy is considered could improve inner ear function. Improvement hearing function usually occurs within a few days after the procedure. Some studies disclosed that hearing loss could occur after CSF shunt insertion. Other published cases reported that CSF shunting had corrected hearing loss.<sup>7,8-10</sup>

The purpose of this paper was to report a case of hydrocephalus with sensorineural hearing loss, and to study how hydrocephalus cause hearing loss.

## CASE REPORT

A girl aged 1 year seven months old, was consulted by a pediatrician with hydrocephalus and global developmental delay, for a hearing

examination. According to her mother, the subject had not been able to speak. There was no history of ear discharge. During pregnancy, the mother had attended regular medical check-ups at a maternity clinic. Ultrasound examination at 7 months of gestation revealed fluid accumulation in the baby's head. The baby was born by caesarean surgery, full term, birth weight 3.500 grams, head circumference 38 cm, and crying loudly after birth. Post-natal history of basic immunization was incomplete. So far, the child had not been able to lift her head or sit up, she could only lie face up on her back, or prone. Physical examination found her general condition was normal, weight 11.2 kg, head circumference 55.3 cm. Physical examination of ears, nose and throat were normal.



**Figure 1. Patient profile**

Routine laboratory results showed within normal limits. TSHs 1.2 IU/ml (negative), free T4 11.60 pmol/L (negative). IgG anti-Toxoplasma 0 IU/ml, IgM anti-toxoplasma 0.06 IU/ml (negative), IgG anti-CMV 53 IU/ml, IgM anti-CMV 0.09 IU/ml (negative). The results of the Oto Acoustic Emission (OAE) test of the right and left ears were 'refer'; the tympanometry result of the right ear was type A, and the left ear was type C; and the results of the right ear Auditory Brainstem Response (ABR) wave 5 detected at 50 dB, the left ear wave 5 detected at 100 dB.

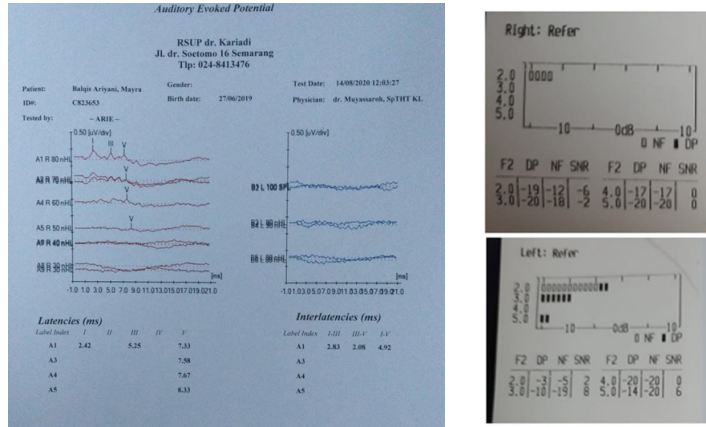


Figure 2. Results of ABR and OAE

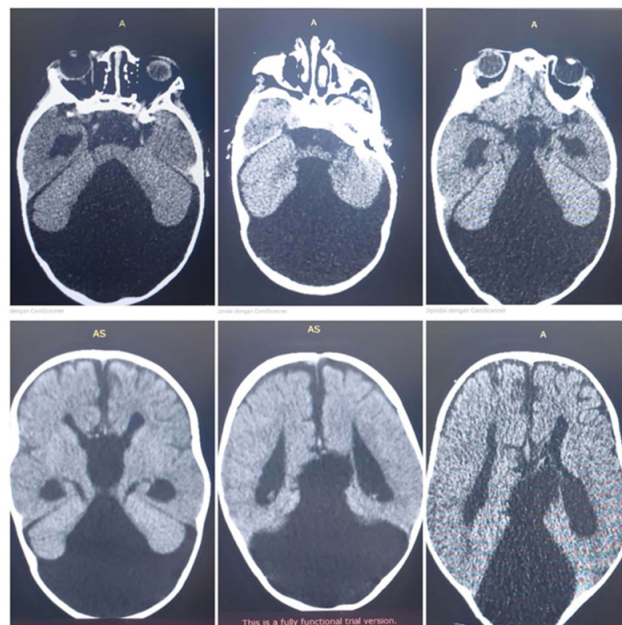


Figure 3. MSCT brain without contrast

The results of Multislice Computerized Tomography (MSCT) scan of the head without contrast showed widening of the fourth ventricle which extended to the posterior fossa with hypoplasia of the cerebellum; no vermis structure was seen with high riding tentorium causing pons pressing, presenting Dandy-Walker image.

The growth and development of the girl were not in accordance with her age. The child was diagnosed with speech delay, with moderate degree of sensorineural hearing loss (SNHL) in the right ear, and profound SNHL in the left ear, and accompanied by hydrocephalus.

The patient underwent ventriculoperitoneal (VP) shunt surgery by a neurosurgeon. Afterwards she underwent physiotherapy and speech therapy. Evaluation was carried out for 3 months, and the growth and development were still not good, the child was not able to lift her head strongly, and very limited respond to sound. But, at 6 months evaluation her response to sound was better, she turned her head to the sound source.

**CLINICAL QUESTION**

How can hydrocephalus cause hearing loss?

## METHOD

Literature search was carried out through PubMed, and Google Scholar, with the keywords “hearing loss” AND

“hydrocephalus” AND “children” obtained 101 journals. From 101 literatures, 4 case reports met the inclusion criteria.

## RESULT

**Table 1. Literature review of case reports**

No	Authors-journal	Patient characteristics	Workup	Procedure	Evaluation after procedure
1.	Karabağlı H, Duru S, Imer M, Apuhan. T. 2011. <sup>6</sup>	Pediatric patients with severe hearing loss due to communicating hydrocephalus.	Case report of hearing loss in hydrocephalus and insertion of a VP shunt	VPshunt insertion	Hearing improved in 2 weeks. Within 3 years post-operative hearing became normal.
2.	Karabağlı H, Duru S, Imer M, Apuhan. T. 2011. <sup>7</sup>	4 months old boy, bilateral hearing loss with hydrocephalus.	Audiometry examination	Endoscopic ventriculostomy and insertion of a VP shunt.	Improvement of intracranial pressure and hearing.
3.	Jamshidi A, Glidewell, C Murnick J, _Magge S, Reilly BK. 2017 <sup>8</sup>	10-month-old child with bilateral sensorineural hearing loss due to hydrocephalus.	case report of hearing loss in hydrocephalus and insertion of a VP shunt	VPshunt insertion	Hearing improvement occurred postoperatively, and better hearing in follow-up examinations.
4	Dixon JF, Jones RO. 2012. <sup>9</sup>	14-years-old girl with sudden hearing loss, tinnitus, and headache.	Audiogram detected SNHL in right ear, MRI showed hydrocephalus	Ventriculostomy without shunt	2 months post-operative, headache and hearing loss improved, audiogram results were normal.

## DISCUSSION

Hydrocephalus is one of the complications due to compression of the fourth ventricle, impairing the flow of cerebrospinal fluid. Hydrocephalus can cause hearing loss directly or indirectly, as the effect of mass compression, cochlear and nuclear nerve dysfunction, complications of prematurity and genetic syndrome.<sup>3,11</sup> (Fig.4)

In our reported case, a child with hearing loss was found with hydrocephalus. Diagnosis of hydrocephalus was based on MSCT results. The results of the OAE examination, tympanometry, and ABR showed hearing impairment.

The occurrence of hearing loss in hydrocephalus is based on the hydrodynamic concept. The anatomy of the perilymph and endolymph systems is closely related to the CSF through two structures, which are cochlear aqueduct and the endolymphatic sac. (Fig.5)

The hydrodynamic theory affirms that excessive or low CSF pressure is transmitted to the inner ear fluid (perilymph and/or endolymph), and thereby changing inner ear pressure, which can cause some degree of hearing loss. CSF hypotension causes a decrease in perilymphatic pressure which results in relative endolymphatic hydrops. In

contrast, increased CSF and perilymphatic pressure result in relative perilymphatic hydrops.<sup>12</sup>

Hearing loss associated with CSF pressure are potential to be repaired. Several investigators described the onset or the resolution of hearing loss with CSF shunting.<sup>5</sup>

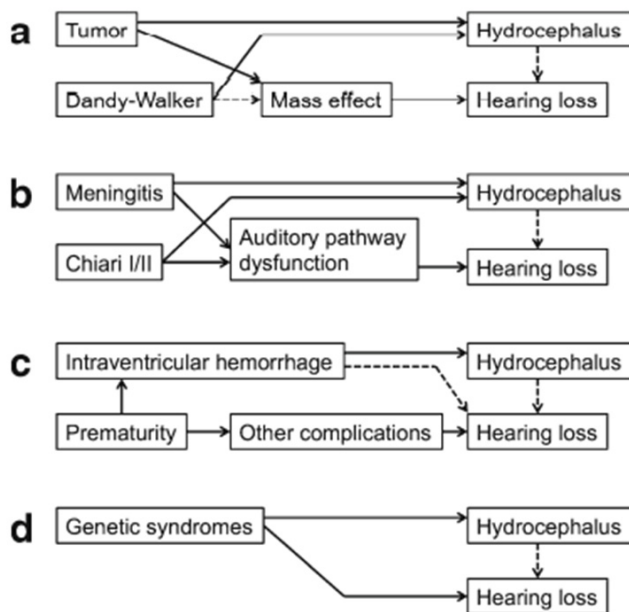


Figure 4. The incidence of hydrocephalus<sup>11</sup>

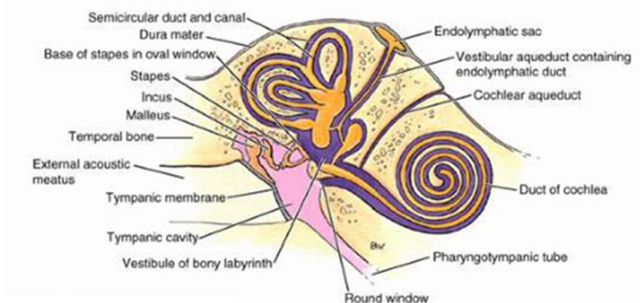


Figure 5. Anatomy of perilymphatic and endolymphatic system<sup>1,2</sup>

It had been reported that in some cases of hydrocephalus and bilateral hearing loss in infants and children, endoscopic ventriculostomy and VP shunt insertion had caused improvement in intracranial pressure and better hearing. Another study reported that hearing became normal after 3 years post-operatively.<sup>8-10</sup>

A prospective study conducted by Lim et al.<sup>13</sup> on nine patients with communicating

hydrocephalus who underwent audiological testing before shunting, 5 days and 1 month after shunt placement. In 40% of patients, the pure tone threshold increased by at least 15 dB at one or more frequencies. This finding suggested that hearing loss after VP shunting is associated with distention of the endolymphatic compartment.

Four clinical studies performed pre-and post-surgery hearing examinations for CSF

Shunt placement and found an onset of post-operative hearing loss. Previous research by Van Veelen et al. studied 16 patients with normal pressure hydrocephalus, found that 64% of the ear showed hearing loss of greater than 10dB. Hearing loss decreased in 75% within 6-12 weeks after shunting.<sup>11</sup>

Hearing loss is more common after surgical procedures that cause the decrease of CSF. Walsted et al. cited by Satzer et al.<sup>11</sup> found an increase in post-operative hearing threshold (relative to pre-operative baseline) in 48% of neurosurgery patients. Sixteen percent of patients underwent extracranial otolaryngological procedures.<sup>1</sup> A follow-up study found that the incidence and magnitude of hearing loss increased with the amount of CSF loss.

The alteration of hearing function with CSF shunting is of particular clinical concern because it demonstrates that CSF pressure-related hearing loss is potentially curable. Some investigators reported the incidence and characteristics of hearing loss in patients with CSF shunt, while other studies and case reports described the onset or resolution of hearing loss with CSF shunting.<sup>14</sup> The Edwards study cited by Satzer et al.<sup>11</sup>, compared ABR outcomes between newborns with congenital hydrocephalus and controls. Eleven of 16 (69%) hydrocephalus infants showed ABR abnormalities on initial testing. Nine of the 11 were re-tested at 3 months, and 7 (78%) showed an increase of 30 dB or more. Among hydrocephalus newborns, the I and V waves are smaller and have a longer latency, and the V/I amplitude ratio is much smaller. These findings suggested that peripheral and central hearing loss improved over time which may reflect cochlear and brainstem nerve dysfunction was due to the effects of altered CSF pressure.<sup>14</sup>

Of the 70 studied patients, 17 (24%) had hearing loss (10 bilateral and 7 unilateral), and all of them had sensorineural hearing loss, which was associated with low weight

at birth, post-hemorrhagic hydrocephalus and brainstem symptoms at the time of diagnosis of hydrocephalus. Hearing pathology was found more often in shunt-treated patients with normal neuro-psychological development (NPD) retardation, poor functional status and low quality of life. Children with shunt-treated hydrocephalus had hearing loss of sensorineural type. Children with brain stem symptomatology at diagnosing hydrocephalus and children with post-hemorrhagic hydrocephalus showed higher risk of hearing loss. Children with shunted hydrocephalus and hearing loss showed lower NPD, lower quality of life and lower functional status.<sup>15</sup>

Some clinical studies had officially tested hearing before and after CSF shunt insertion and found post-operative onset of hearing loss. Post VP shunting hearing improvement was observed in 14 patients (70%) whereas it worsened in 30% of patients. The result could be even better if shunt is placed at early age.<sup>16</sup>

Merchant et al. quoted by Satzer et al.<sup>11</sup> and Guillaume et al.<sup>17</sup> investigated the association between CSF shunting and hearing loss using clinical trial data on brain tumor treatment. Children in this trial underwent radiation, ototoxic chemotherapy, and/or insertion of a CSF shunt were reported high-frequency hearing loss in all children with shunts. They found high-frequency hearing loss in all shunting children but only 70% of non-shunting children, resulting in a very high odds ratio of 23 for hearing loss after CSF shunting. The side of the shunt and the diameter of the cochlear aqueduct did not correlate with hearing loss. Merchant et al. found that hearing loss was worst in patients who received a CSF shunt as well as radiation and chemotherapy; and low and middle frequencies were most affected.<sup>11</sup>

Sammons et al.<sup>6</sup> reported a case of a 13-years-old male with severe bilateral SNHL and idiopathic hydrocephalus. Insertion of a ventriculoperitoneal (VP) shunt resulted in

improvement of his hearing on the 2nd post-operative day and complete resolution after 2 months.

Another report described three patients with aqueductal stenosis who presented with hearing loss and tinnitus. Two cases with fluctuating hearing loss and vertigo, and audiological assessment revealed labyrinthine pathology. One case recovered the hearing after insertion of an external ventricular drain (EVD). The second case that underwent VP shunt insertion experienced resolution of hearing loss. The third case underwent ventriculoatrial (VA) shunting, but the atrial catheter was deemed nonfunctional and replaced in the cisterna magna, the hearing loss resolved after ventriculocisternal shunting. CSF cisternal pressure could be elevated in a patient with hydrocephalus associated with aqueductal stenosis. Insertion of a VP or EVD shunt could reduce cisternal CSF pressure directly or by equalizing pressure from the lateral and third ventricles (in aqueductal stenosis). Ventriculocisternal shunting for aqueductal stenosis allowed ventricular and cisternal CSF pressures to fall to the normal range. In all cases, CSF diversion resolved the suspicion of perilymphatic hydrops.<sup>9</sup>

In our case report, the authors presented a child with hearing loss and hydrocephalus. Diagnosis of hydrocephalus was based on MSCT results. She did not respond to sound and could not lift her head. The results of the OAE examination, tympanometry, and ABR showed bilateral hearing impairment.

The patient underwent VP Shunt insertion. At a 3-month evaluation the child sometimes responded to sound, at 6-month evaluation the child responded more to sound.

In conclusion, a VP shunt had been inserted on a girl aged 1 year 7 months with hydrocephalus hearing loss who did not respond to sound. At 3 months of evaluation, she was able to respond to sound, and the response was better after 6 months.

Hydrocephalus could cause hearing loss through compression of the fourth ventricle which affects CSF pressure. This condition causes endolymph hydrops which results in impaired inner ear function.

## REFERENCE

1. Greenberg MS. Handbook of Neurosurgery. 7th ed. Thieme, New York; 2010.
2. Swartz JD, Mukherji SK. The inner ear and osteodystrophies. In: Swartz JD, Loevner LA, editors. Imaging of the Temporal Bone. 4th ed. Thieme, New York; 2011. p. 298-411.
3. Mohammed H, Elsatar AEA, Ragab M, Algriany A. Evaluation of Late Onset Congenital Aqueductal Stenosis Hydrocephalus. *J Neurol Stroke*. 2016; 5(1).
4. Alwan M, Hurtado G. Unilateral permanent sudden sensorineural hearing loss after spina-epidural anaesthesia for caesarean section: a case report. *Journal of Surgical Case Reports*. 2019 Dec 1;2019(12).
5. Mostafa BE, El-Sersy HAA, Hamid TA. Increased intracranial tension and cochleovestibular symptoms: an observational clinical study. *Egypt J Otolaryngol*. 2018; 34(3):191-3.
6. Sammons VJ, Jacobson E, Lawson J. Resolution of hydrocephalus-associated sensorineural hearing loss after insertion of ventriculoperitoneal shunt: *J Neurosurg Ped*. 2009; 4(4):394-6.
7. Karabagli H, Duru S, Imer M, Apufan T. Improvement of non-syndromic Hearing Loss After Treatment of High Cerebrospinal Fluid Pressure. A Case Report. *J Neurol Sci Turk*. 2011;28(2):258-64.
8. Jamshidi A, Glidewell C, Murnick J, Magge S, Reilly BK. Resolution of bilateral sensorineural hearing loss following ventriculoperitoneal shunt and literature review. *Int J Ped Otorrhinol*. 2017; 100:141-4.
9. Dixon JF, Jones RO. Hydrocephalus-associated hearing loss and resolution after ventriculostomy. *Otolaryngol HN Surg (USA)*. 2012; 146(6):1037-9.

10. Crea KN, Shivdasani MN, Argent RE, Mauger SJ, Rathbone GD, O'Leary SJ, et al. Acute cochlear nucleus compression alters tuning properties of inferior colliculus neurons. *Audiol Neurotol.* 2009; 15(1):18-26
11. Satzer D, Guillaume DJ. Hearing loss in hydrocephalus: a review, with focus on mechanisms. *Neurosurg Rev.* Springer Verlag. 2016; 39:13-25.
12. Bell A. How Do Middle Ear Muscles Protect the Cochlea? Reconsideration of the Intralabyrinthine Pressure Theory. *J Hear Sci.* 2011; 1(2):9-23.
13. Lim HW, Shim BS, Yang CJ, Kim JH, Cho YH, Cho YS, et al. Hearing loss following ventriculoperitoneal shunt in communicating hydrocephalus patients. *Laryngoscope.* 2014; 124(8):1923-7.
14. Ozturk S, Erol FS, Akgun B, Kaplan M, Birkent OF, Karlidag T. Evaluation of hearing function by auditory brainstem response in newborn patients with hydrocephalus before and after ventriculoperitoneal shunt surgery. *Ped Neurosurg.* 2016; 51(4):183-90.
15. Panova M, Geneva IE, Madjarova KI, Bosheva MN. Hearing Loss in Patients with Shunt-Treated Hydrocephalus. *Fol Med.* 2015; 57(3-4):216-22.
16. Verma M, Singh J, Singh I, Kakkar V, Yadav SPS, George JS. To Evaluate the Pre and Post Shunt Sensorineural Hearing Loss in Hydrocephalus Patients. *Indian J Otolaryngol HN Surg.* 2019; 71:1314-9.
17. Guillaume DJ, Knight K, Marquez C, Kraemer DF, Bardo DME, Neuwelt EA. Cerebrospinal fluid shunting and hearing loss in patients treated for medulloblastoma. *J Neurosurg Ped.* 2012; 9(4):42-7.