

Case report**Lennox-Gastaut syndrome and its impact on quality of life:
hearing and speech perspective**

**Semiramis Zizlavsky*, Shally Adhina Putri*, Indra Parmaditya Pamungkas *,
Khoirul Anam*, Irawan Mangunatmadja****

*Department of Otorhinolaryngology Head and Neck Surgery,

**Department of Paediatric,

Faculty of Medicine, Universitas Indonesia / Dr. Cipto Mangunkusumo Hospital, Jakarta

ABSTRACT

Background: Lennox-Gastaut syndrome (LGS) is a severe pediatric epilepsy syndrome characterized by multiple seizure types including tonic, atonic, atypical absence, and generalized tonic-clonic seizures. LGS is also associated with cognitive decline and various neural disturbance, including hearing loss. **Purpose:** To report a case of Lennox-Gastaut syndrome with unilateral hearing loss and delayed speech. **Case report:** Four years old boy with LGS and delayed speech was referred to the Otolaryngology Outpatient Clinic, Dr Cipto Mangunkusumo Hospital for hearing and speech ability evaluation. He had had repeated seizures since he was three weeks old, and also had cortical lesion and mild atrophy in the left hemisphere brain. Hearing tests with Otoacoustic Emission (OAE), Brainstem Evoked Response Audiometry (BERA), and Auditory Steady State Response (ASSR) revealed profound unilateral hearing loss in the left ear, which required hearing aid and also speech therapy. **Clinical question:** Is there any correlation between brain abnormality/damage with unilateral hearing loss and delayed speech in Lennox-Gastaut syndrome? **Method:** Using Pubmed, Proquest Database, and Hand Searching to search the evidence. The evidence selected will be appraised by at least two members of our group using Oxford Center of Evidence-Based Medicine (CEBM) worksheet. **Result:** Following screening of double publication and its suitability to our clinical questions over ten years, no literature was found. **Conclusion:** The patient was given antiepileptic drugs (AEDs) and postural control training. For the hearing and speech problems, as the best comprehensive treatment the patient was suggested to use hearing aids and undergo speech therapy program.

Keywords: delayed speech, hearing loss, Lennox-Gastaut syndrome, seizure

ABSTRAK

Latar belakang: Lennox-Gastaut syndrome (LGS) adalah kumpulan gejala epilepsi berat pada anak dengan ciri khas kejang multipel, tonik, atonik, kejang absans atipik dan tonik klonik menyeluruh. LGS juga berkaitan dengan penurunan kognitif dan berbagai gangguan saraf, termasuk gangguan pendengaran. **Tujuan:** melaporkan kasus sindrom Lennox-Gastaut dengan gangguan pendengaran satu sisi dan keterlambatan bicara. **Laporan Kasus:** Seorang anak laki-laki berusia 4 tahun dengan sindroma Lennox-Gastaut mengalami keterlambatan bicara dirujuk ke Departemen Telinga Hidung Tenggorok, Rumah Sakit Dr. Cipto Mangunkusumo untuk evaluasi ambang dengar dan penanganannya. Riwayat penyakit menunjukkan kejang berulang sejak berusia tiga minggu, yang ditemukan juga lesi di korteks serebri dan atrofi ringan pada hemisfer otak kiri. Berdasarkan Otoacoustic Emission (OAE), Brainstem Evoked Response Audiometry (BERA), dan Auditory Steady State Response (ASSR) ditemukan adanya gangguan pendengaran sangat berat unilateral pada telinga kiri dan membutuhkan Alat Bantu Dengar dan terapi wicara. **Pertanyaan klinis:** Apakah terdapat korelasi antara abnormalitas otak atau kerusakan otak dengan gangguan pendengaran unilateral dan keterlambatan bicara pada LGS? **Metode:** Pencarian bukti dilakukan melalui PubMed, Proquest, dan pencarian manual. Artikel yang didapatkan kemudian ditelaah oleh setidaknya dua anggota kelompok dengan menggunakan lembar

kerja yang diperoleh dari Oxford Center of Evidence-Based Medicine (CEBM) Hasil: Setelah dilakukan skrining publikasi ganda dan kesesuaian dengan pertanyaan klinis dari sepuluh tahun terakhir tidak ditemukan literatur yang sesuai. Kesimpulan: Pasien ditangani dengan obat antiepilepsi dan latihan psikomotorik. Untuk gangguan pendengaran pasien dianjurkan untuk menggunakan Alat bantu Dengar dan terapi wicara. Penanganan kasus LGS harus menyeluruh untuk memperoleh hasil yang baik.

Kata kunci: keterlambatan bicara, penurunan pendengaran, sindrom Lennox-Gaustat, kejang

Correspondence address: Semiramis Zizlavsky. Department of Otorhinolaryngology, Head and Neck Surgery, Faculty of Medicine, Universitas Indonesia, RSUPN Dr.Cipto Mangunkusumo, Jl.Diponegoro 71 Jakarta. Email: semiramiszizlavsky@gmail.com

INTRODUCTION

Lennox-Gastaut Syndrome (LGS) is a severe pediatric epilepsy syndrome characterized by multiple seizure types including tonic, atonic, atypical absence, and generalized tonic-clonic seizures. The prevalence of LGS is estimated between 1-2% of all patients with epilepsy. LGS typically develops between 3-5 years of age and is more common in males. Most children with LGS (75%) have an underlying structural brain abnormality or brain damage. These include developmental cortical malformations, neurocutaneous syndromes, post hypoxic-ischemic insult, meningitis/encephalitis, or metabolic encephalopathy.^{1,2} To the best of our knowledge, there were no specific study about management of hearing loss in Lennox-Gastaut syndrome currently available.

CASE REPORT

Reporting a four years-old boy with history of LGS. He did not respond to the sound from the left side, but there was minimal movement of the head when he was called from the right side. No history of ear infection nor trauma. He was born through caesarean section due to preeclampsia within 38 weeks of gestation, normal birth weight with no asphyxia, and he also had a history of neonatal jaundice. Since three months old, the patient had had repeated seizures which might occur more than 10 times a day, each lasting

for about one minute with poor response to conventional treatment. After he had been given combination of antiepileptic drugs (AED) at the age 2 years old, fortunately the seizure had improved.

Patient had global developmental delay. Currently, he was still unable to walk. As far as speech development, he was currently still babbling and unable to follow simple instructions. One year previously patient underwent Brain MRI and the result showed focal lesion suggestive of laminar necrosis at left frontal lobe cortex and mild atrophy of left temporal lobe. (Figure 1).

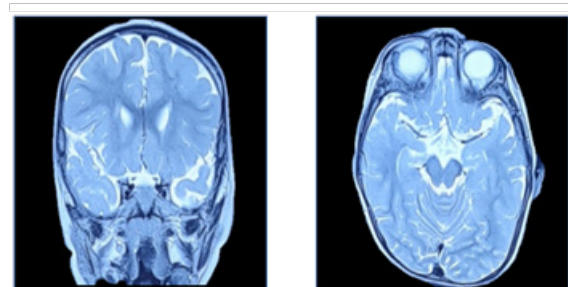


Figure 1. Brain MRI showed abnormality in left frontal and temporal lobe

Patient was then referred by Pediatric Department for further hearing evaluation. Complete auditory examination performed through otoscopy, tympanometry, OAE (Otoacoustic Emissions), Evoked-ABR (Evoked-Auditory Brain Response), and ASSR (Auditory Steady State Response). Otoscopy were normal in both ears. The

tympometry revealed type A in both ears. The OAE showed disruption of the cochlear outer hair cells emissions in the left ear, but normal in the right ear. ABR with click and tone burst 500 Hz stimulus revealed a good response at 20 dB on the right ear. On the left ear, the fifth electrophysiological wave of ABR was not detected until 90 dB. The ASSR showed profound sensorineural hearing loss in the left ear. (Figure 2).

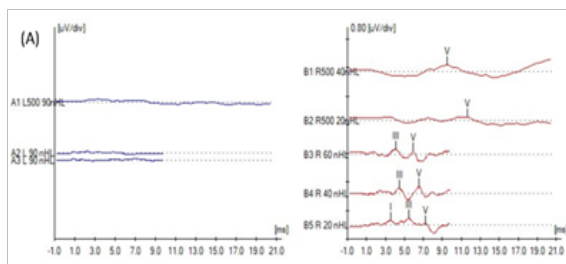


Figure 2. ABR result showed profound unilateral hearing loss in left ear

The EEG was then conducted and revealed frequent runs of rhythmic 1.5-2.5Hz diffuse multiple slow-spike and-wave (SSW), frequent basic rhythmic wave 2-3 followed by generalized medium-voltage fast activity (MVFA) 1-2, and intermittent burst suppression. (Figure 3).

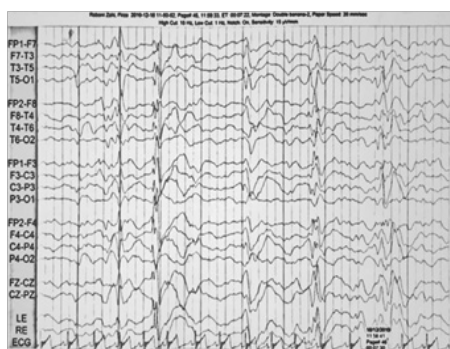


Figure 3. EEG

CLINICAL QUESTION

Is there any correlation between brain abnormality or brain damage with unilateral hearing loss and delayed speech in Lennox-Gastaut syndrome?

METHOD AND RESULT

In this review, we analyzed the impact of LGS to patient's quality of life in the term of hearing and speech. We formulated our clinical question: (P) Patients with LGS; (I) no intervention was assigned; (C) no comparator was assigned; (O) Hearing and speech impairment.

We defined the keywords based on PICO and literature searching was performed through PubMed/Medline, Proquest, EBSCO Host and Cochrane databases. Searching process was carried out by boolean operator using keywords such as "Lennox Gaustat Syndrome" AND "Hearing Loss" OR "Deafness" OR "Speech Delay" OR "Delayed Speech". We also included manual hand searching through Google Scholar search engine. Searching was performed systematically using inclusion and exclusion criteria. The inclusion criteria for this evidence-based case report were:

1. The study design was systematic review or meta-analysis of observational studies (cohort, case control, retrospective review), primary studies (cohort, case control, cross sectional).
2. Study related to the evidence of hearing and speech impairment in patients with LGS.
3. Study on human.

The exclusion criteria were:

1. Published study was not available as full text journal.
2. Study was not published in English or Bahasa Indonesia.
3. Study was critically appraised using FAITH for systematic review or meta-analysis, and CEBM Oxford for the primary studies.

Based on following screening of double publication and its suitability to our clinical questions over ten years, no literature was

found. It indicated that the study towards hearing and speech aspect in patients with LGS remained scarce, it might be due to very rare findings of LGS case (0.1-0.28 case per 100,000 lives per year).

DISCUSSION

Patients with LGS frequently showed cognitive regression at the time of diagnosis, while established LGS is almost always associated with moderate to severe cognitive impairment. About 60% of patients showed intellectual disability at the time of diagnosis, increasing to 75-95% within 5 years of the syndrome's onset. Our patient's IQ test had already performed when he was 4 years old and revealed severe intellectual disability (IQ score: 20-35). The social maturity index was far below his actual age, and the verbal performance scale was not able to be assessed during the evaluation. SNHL in children will lead to impaired auditory perception, due to the lack of auditory stimulus and neurosensory disintegration in central auditory network. Impaired of neurosensory integration in fronto-parietal and fronto-striatal pathway will affect cognitive function and will manifest as attention, perception, and memory disorders. Development of neurosensory plasticity in primary auditory cortex will occur after rehabilitation, it will enhance the auditory stimulation in neural conductivity.³

Cognitive impairment in LGS appears to be related to the age of onset and persistence of seizures. An earlier age of seizure onset (<5 years) has been associated with more severe cognitive impairment, while patients who develop LGS later in life (>9 years) follow a more favorable cognitive course.^{1,3,4} Warren et al.⁵ in their research found that 8 out of 15 cases of LGS (<4 years of age) had moderate to severe cognitive impairment. All of these patients were minimally verbal or nonverbal affected and need assistance in their daily living. Our patient had a history

of prolonged seizure since 3 months of age. He also had global developmental delay and unilateral profound hearing loss with speech delay. MRI results showed focal lesion suggestive of laminar necrosis at left frontal lobe cortex and mild atrophy of left temporal lobe, supported by EEG result. In particular, atypical and atonic seizure in LGS patient may be associated with focal brain lesions in the frontal or temporal lobes.

The result of ABR and ASSR suggested profound sensorineural hearing loss in the left ear. Based on literature, there was association between brain damage or abnormality with unilateral hearing loss and delayed speech. The Broca's area is located 99% in left hemisphere with its function linked to auditory and linguistic processing. It is well known that the planum temporal (PT) area in the posterior lobe carries out analysis of auditory stimuli, which is crucial for speech. Brain damage or abnormality near to or including the left PT are associated with deficits of auditory discrimination and or speech comprehension. Several empirical findings suggest that beyond auditory perception the PT may play an active part in auditory attention.^{6,7}

We suggested for the patient to use hearing aid to manage unilateral hearing loss, but the patient did not get the device until 4 years old of age because his parents were still focused on the management of his seizures. At the of age of 4 years old, patient was just beginning to be able to walk a few steps, and to respond when someone called his name, and uttered two to three simple words. The other important aspects in treating this patient were also related to his severe intellectual disability. It might affect the learning process and his future growth and development. In this case, the goals of treatment were to teach the patient for comprehending spoken language and producing appropriate communicative behavior with the help of hearing aid. It was also important to educate and motivate the parents in encouraging their children's communication skills.

Lennox-Gastaut Syndrome (LGS) is a severe pediatric epilepsy syndrome with multi-neurological involvement. The hearing and speech disorders are some of the manifestations that would potentially affect the quality of life. Therefore, comprehensive multidisciplinary management is needed to achieve patients' best outcomes.

single-sided deafness is not improved when listening with a bone-conduction device. *Hear Res* [Internet]. 2019; 372:62-8. Available from: <https://doi.org/10.1016/j.heares.2018.04.007>

ACKNOWLEDGMENTS

The author declares no conflict of interest and no funding was received for this study.

REFERENCE

1. Al-Banji MH, Zahr DK, Jan MM. Lennox-Gastaut syndrome: Management update. Vol. 20, *Neurosciences*. 2015. p. 207-12.
2. Asadi-Pooya AA. Lennox-Gastaut syndrome: a comprehensive review. *Neurol Sci*. 2018; 39(3):403-14.
3. Xia S, Song T, Che J, Le Q, Chai C, Zheng M, et al. Altered brain functional activity in infants with congenital bilateral hearing loss: A resting-state functional MRI study. *Neural Plast*, 2017;8986362.
4. Jahngir MU, Ahmad MQ, Jahangir M. Lennox-Gastaut Syndrome: In a Nutshell. *Cureus*. 2018; 10(8):1-8.
5. Warren AEL, Abbott DF, Vaughan DN, Jackson GD, Archer JS. Abnormal cognitive network interactions in Lennox-Gastaut syndrome: A potential mechanism of epileptic encephalopathy. *Epilepsia*. 2016; 57(5):812-22.
6. Forseth KJ, Hickok G, Rollo PS, Tandon N. Language prediction mechanisms in human auditory cortex. *Nat Commun* [Internet]. 2020; 11(1):1-14. Available from: <http://dx.doi.org/10.1038/s41467-020-19010-6>
7. Hirnstein M, Westerhausen R, Hugdahl K. The Right Planum Temporale Is Involved in Stimulus-Driven, Auditory Attention - Evidence from Transcranial Magnetic Stimulation. *PLoS One*. 2013; 8(2):1-7.
8. Agterberg MJH, Snik AFM, Van de Goor RMG, Hol MKS, Van Opstal AJ. Sound-localization performance of patients with